

PAM EXAMINATION: SAMPLE CASE 4

Demographics

62-year-old white female; travel agent

Chief complaint

decreasing vision

History of present illness

Character/signs/symptoms: blurred vision

Location: OD

Severity: severe

Nature of onset: gradual

Duration: 6 months

Frequency: constant

Exacerbations/remissions: none

Relationship to activity or function: none

Accompanying signs/symptoms: none

Secondary complaints/symptoms

eyes feel scratchy all day

Patient ocular history

corneal abrasion OS at age 45

Family ocular history

father: macular degeneration

Patient medical history

rheumatoid arthritis

Medications taken by patient

Plaquenil® 200 mg per day for 2 years

Patient allergy history

hayfever; NKDA

Family medical history

mother: diabetes

Review of systems

Constitutional/general health: malaise

Ear/nose/throat: denies

Cardiovascular: denies

Pulmonary: denies

Dermatological: denies

Gastrointestinal: denies

Genitourinary: denies

Musculoskeletal: joint pain

Neuropsychiatric: denies

Endocrine: denies

Hematologic: denies

Immunologic: denies

Mental status

Orientation: oriented to time, place, and person

Mood: appropriate

Affect: appropriate

Clinical findings

Habitual spectacle Rx:	<u>VA Distance</u>	<u>VA Near (with Add)</u>
OD: +1.50 -0.50 x 085	20/200	20/200
OS: +2.00 -0.75 x 090	20/20	20/20
+2.50 D Add		

Pupils: PERRL, negative APD

EOMs: full, no restrictions

Confrontation fields: full to finger counting OD, OS

Subjective refraction:	<u>VA Distance</u>	<u>Pinhole</u>	<u>VA Near (with Add)</u>
OD: +1.75 -0.75 x 090	20/200	no improvement	20/200
OS: +1.75 -0.50 x 095 +2.50 D Add	20/20		20/20

Amsler grid:

OD: see **Image 1**

OS: see **Image 2**

Slit lamp:

lids/lashes/adnexa: unremarkable OD, OS

conjunctiva: normal OD, OS

cornea: clear OD, OS

anterior chamber: deep and quiet OD, OS

iris: normal OD, OS

lens: 1+ nuclear sclerosis OD, OS

vitreous: posterior vitreous detachment OD, syneresis OS

IOPs: 14 mmHg OD, 14 mmHg OS @ 11:20 AM by applanation tonometry

Fundus OD:

C/D: 0.4H/0.45V

macula, posterior pole: see **Image 3**

periphery: scattered pavingstone degeneration 360°

Fundus OS:

C/D, macula, posterior pole: see **Image 4**

periphery: scattered pavingstone degeneration 360°

Blood pressure: 134/82 mmHg, right arm, sitting

Pulse: 76 bpm, regular

Image 2: OS





Image 1: OD



Note: When visual fields are displayed side-by-side, the OD visual field will be on the right and the OS visual field will be on the left.

Image 3: OD

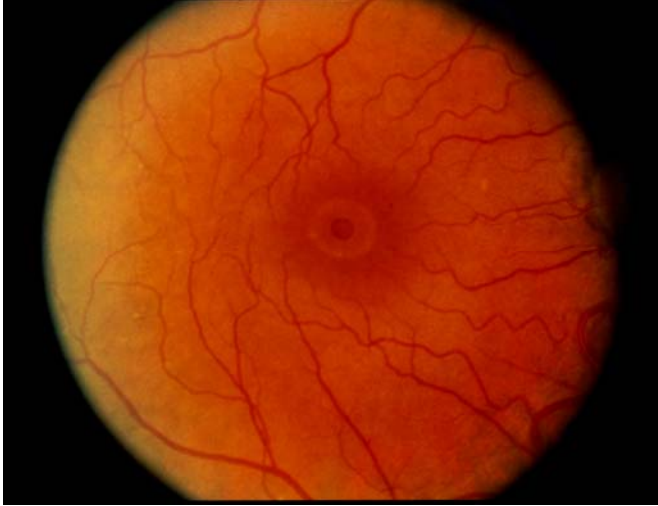
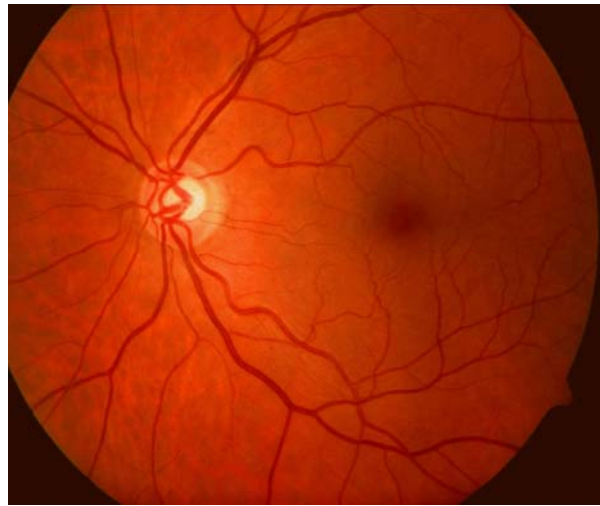
Image 4: OS



correct answer

1. The **MOST** likely diagnosis of the patient's fundus condition OD is: **(Diagnosis)**
 - a. bull's eye maculopathy.
 - b. histoplasmosis.
 - c. wet age-related maculopathy.
 - d. solar retinopathy.
 - e. macular hole.

2. The **MOST** likely etiology of the patient's fundus condition OD is: **(Clinical Correlation of Basic Science Principles)**
 - a. drug toxicity.
 - b. stimulation of new blood vessel growth.
 - c. vitreous traction.
 - d. systemic infection.
 - e. thermal damage.

3. If the patient manifests progressive lenticular changes and an increase in myopia, which of the following types of cataracts is **MOST** likely responsible for these clinical signs? **(Clinical Correlation of Basic Science Principles)**
 - a. Anterior cortical
 - b. Nuclear sclerotic
 - c. Cortical
 - d. Posterior polar

4. Which of the following is the **MOST** appropriate management for this patient?
(Treatment / Management)

- a. Annual monitoring
- b. Vitrectomy
- c. Oral prednisone
- d. Laser photocoagulation
- e. Ocuvite®
- f. Anti-VEGF injection

5. Which of the following is **MOST** appropriate to include in the education of this patient?
(Related to Treatment / Management)

- a. Polycarbonate spectacle lenses are important to protect the left eye.
- b. Genetic counseling for the patient's grandchildren is essential.
- c. The patient's rheumatologist should discontinue the Plaquenil®.
- d. Sunglasses should be worn full-time to protect the retina.
- e. Consultation with a pulmonologist should be scheduled.
- f. Low vision aids are necessary for activities of daily living.

6. This patient called your office a week ago and asked for your advice over the phone, prior to scheduling her first appointment. Which of the following describes the circumstance whereby giving professional advice over the telephone can establish a doctor-patient relationship?
(Legal and Ethical Issues)

- a. The telephone conversation is sufficient by itself.
- b. The telephone conversation is sufficient only if payment is tendered for the advice.
- c. The telephone conversation is sufficient only if follow-up care is given in the office.
- d. The telephone conversation is sufficient only if it is an emergency.

Rev 09/2009