

PAM EXAMINATION: PATIENT SAMPLE 3

Demographics

21-year-old Asian male; college student

Chief complaint

problems with contact lenses

History of present illness

Character/signs/symptoms: contact lenses move excessively and are uncomfortable

Location: OD, OS

Severity: mild

Nature of onset: gradual

Duration: 3 months

Frequency: constant

Exacerbations/remissions: worse when moving eyes

Relationship to activity or function: when wearing contact lenses

Accompanying signs/symptoms: itchiness, redness

Secondary complaints/symptoms

wants new back-up spectacles

Patient ocular history

last eye exam 3 years ago; wears opaque/colored conventional soft contact lenses; last replaced 2 years ago; occasionally sleeps with the contact lenses; uses multi-purpose solution

Family ocular history

father: retinal detachment at age 20

Patient medical history

last physical examination 1 year ago

Medications taken by patient

Claritin®

Patient allergy history

seasonal allergies; skin allergies; NKDA

Family medical history

father: prostate cancer

Review of systems

Constitutional/general health: denies

Ear/nose/throat: frequent runny nose

Cardiovascular: denies

Pulmonary: denies

Dermatological: denies

Gastrointestinal: denies

Genitourinary: denies

Musculoskeletal: denies

Neuropsychiatric: denies

Endocrine: denies

Hematologic: denies

Immunologic: denies

Mental status

Orientation: oriented to time, place, and person

Mood: appropriate

Affect: appropriate

Clinical findings

VA with current CLs:	<u>Distance</u>	<u>Near</u>	<u>Pinhole</u>
OD:	20/30	20/30	no improvement
OS:	20/30	20/30	no improvement

Pupils: PERRL, negative APD

EOMs: full, no restrictions

Confrontation fields: full to finger counting OD, OS

Keratometry:

OD: 45.25 @ 180 / 44.50 @ 090; mires slightly distorted

OS: 45.50 @ 180 / 44.75 @ 090; mires slightly distorted

Subjective refraction: VA Distance VA Near

OD: -7.50 DS 20/20 20/20

OS: -8.25 DS 20/20 20/20

Slit lamp:

lids/lashes/adnexa: unremarkable OD, OS

conjunctiva: mild bulbar injection OD, OS; palpebral see **Image 1 OD**, OS similar to OD

cornea: mild diffuse superficial punctate keratitis OD, OS

anterior chamber: deep and quiet OD, OS

iris: normal OD, OS

lens: clear OD, Mittendorf's dot OS

vitreous: clear OD, OS

contact lens assessment: see **Image 2 OD**, OS similar to OD

IOPs: 15 mmHg OD, 17 mmHg OS @ 3:15 PM by applanation tonometry

Fundus OD:

C/D: 0.4H/0.45V

macula: normal

posterior pole: normal

periphery: lattice degeneration without holes 360°

Fundus OS:

C/D: 0.5H/0.5V

macula: normal

posterior pole: normal

periphery: lattice degeneration without holes 360°

Blood pressure: 116/70 mmHg, right arm, sitting

Pulse: 68 bpm, regular

Image 1: following instillation of fluorescein sodium, using cobalt filter

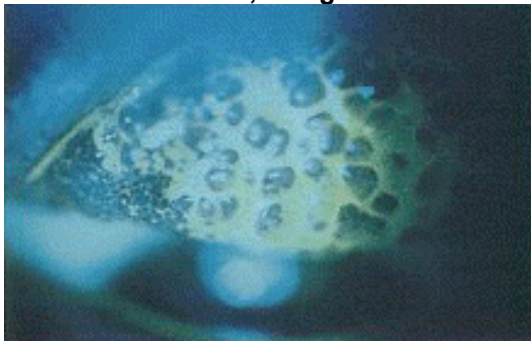



Image 2: contact lens assessment OD



correct answer

1. Which of the following is the **MOST** likely diagnosis of this patient's ocular condition?
(Diagnosis)
 - a. Adult inclusion conjunctivitis
 - b. Bacterial conjunctivitis
 - c. Viral conjunctivitis
 - d. Giant papillary conjunctivitis

2. Which type of antibody is involved in atopic disease?

(Clinical Correlation of Basic Science Principles)

- a. IgA
- b. IgE
- c. IgG
- d. IgM

3. Which of the following is the **MOST** appropriate **INITIAL** treatment for this patient's ocular condition? (Treatment / Management)

- a. Discontinue contact lens wear
- b. Artificial tears
- c. Replace contact lenses
- d. Topical ophthalmic antibiotic

4. Once the patient's condition has resolved, which of the following would be the **MOST** appropriate contact lens wear modality? (Related to Treatment / Management)

- a. Disposable, 1-day daily wear soft
- b. Disposable, 1-week extended wear soft
- c. Frequent replacement, 3-month soft
- d. Conventional daily wear soft

5. When refitting this patient with contact lenses, which of the following contact lens powers is **MOST** appropriate? (Related to Treatment / Management)

- | | <u>OD</u> | <u>OS</u> |
|----|-----------|-----------|
| a. | -6.50 DS | -6.75 DS |
| b. | -7.00 DS | -7.50 DS |
| c. | -7.50 DS | -8.00 DS |
| d. | -8.00 DS | -8.50 DS |

6. Following a successful contact lens fitting, including a period of lens wear, the patient asks for a copy of his contact lens prescription. Which of the following statements **BEST** describes the optometrist's responsibility? (Legal and Ethical Issues)

- a. The optometrist must comply with the patient's request.
- b. The optometrist must provide a prescription with all required contact lens parameters as long as the patient agrees to return for follow-up care.
- c. The optometrist is required to provide a prescription only if the contact lenses are to be purchased elsewhere.
- d. The optometrist does not have to provide a contact lens prescription unless required by state law.

Rev 11/2009